

E-Learning



ESRO:
European School
of Radiation and Oncology



EAGLE

ESTRO Applications for Global Learning



ESTRO 27 /// 14-18 September 2008 /// Göteborg, Sweden

Global Learning



Online lectures



Learning Objects



ESTRO 27 /// 14-18 September 2008 /// Göteborg, Sweden



Navigation system

The screenshot shows a web interface for 'EAGLE ESTRO' with the title 'Evidence and research in rectal cancer'. It features a search bar with the text 'Evidence and research in rectal cancer > Search' and a search button. Below the search bar, there are 'Keywords:' and a list of tags including CRM, MRI, Nodal, Staging, lymphnode, and many others. Two main content cards are displayed: 'Risk Factors' with a list of items (Treatment, CRM, Nodal disease) and 'Take home messages' featuring an ultrasound image and the text 'LUS in expert hands'. The interface is styled with a purple and white color scheme.



Learning Objects

 Course home



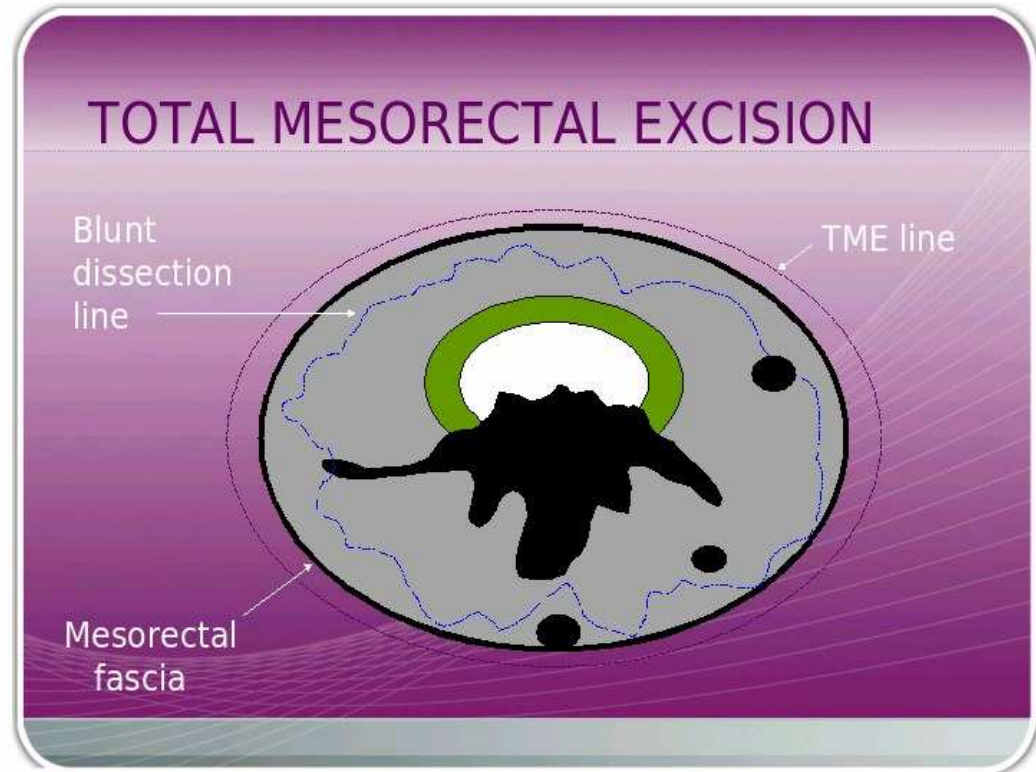
Regina Beets-Tan, Rome,
27-29 March 2008

 11 / 22

87% 

Total mesorectal excision

- TOTAL MESORECTAL EXCISION ✓
- PATHOLOGICAL EXAMINATION OF THE CRM ✓
- Slide3 ✓
- Slide4 ✓
- Slide5 ✓
- Slide6 ✓
- Slide7 ✓
- Slide8
- Slide5
- Slide6 ✓
- Slide7 ✓
- Slide8



Virtual Classroom



Eagle course participants
and
Coaches - Experts



ESTRO 27 /// 14-18 September 2008 /// Göteborg, Sweden



Clinical Cases

? Question 1 : / 3 Will the diagnostician consider enough the stage imaging of the patient?



In a outpatient clinic a patient with rectal cancer will ask a consultation.

There were: the surgeon, the diagnostician, the radiation oncologist and the medical oncologist.

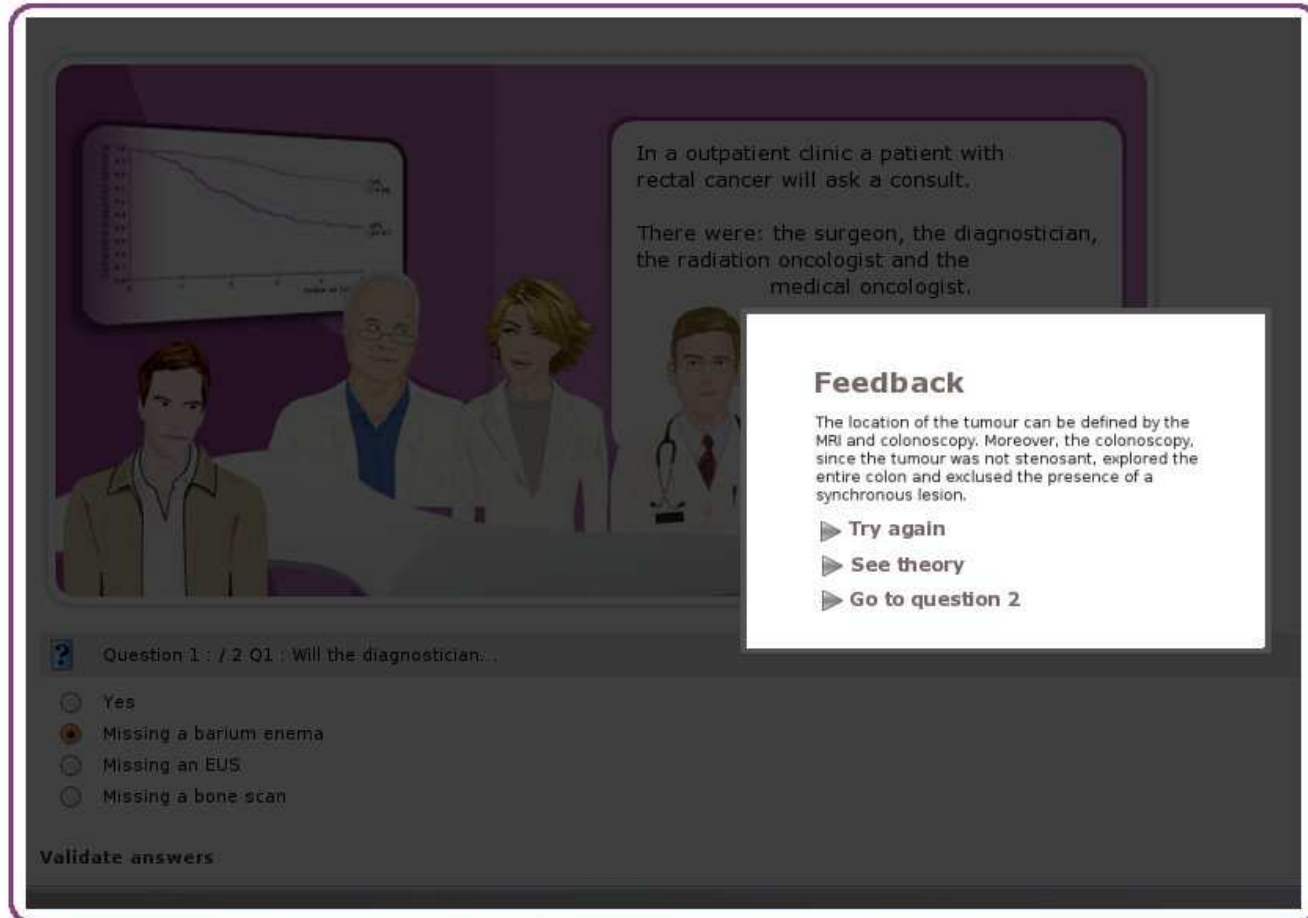
She has with her a colonoscopy and biopsy, a pelvic MRI and a chest abdomen CT scan.

- Yes.
- Missing a barium enema.
- Missing an EUS.
- Missing a bone scan.

Validate answers



Clinical Cases



In an outpatient clinic a patient with rectal cancer will ask a consult.

There were: the surgeon, the diagnostician, the radiation oncologist and the medical oncologist.

Feedback

The location of the tumour can be defined by the MRI and colonoscopy. Moreover, the colonoscopy, since the tumour was not stenosing, explored the entire colon and excluded the presence of a synchronous lesion.

- ▶ Try again
- ▶ See theory
- ▶ Go to question 2.

? Question 1 : / 2 Q1 : Will the diagnostician...

- Yes
- Missing a barium enema
- Missing an EUS
- Missing a bone scan

Validate answers

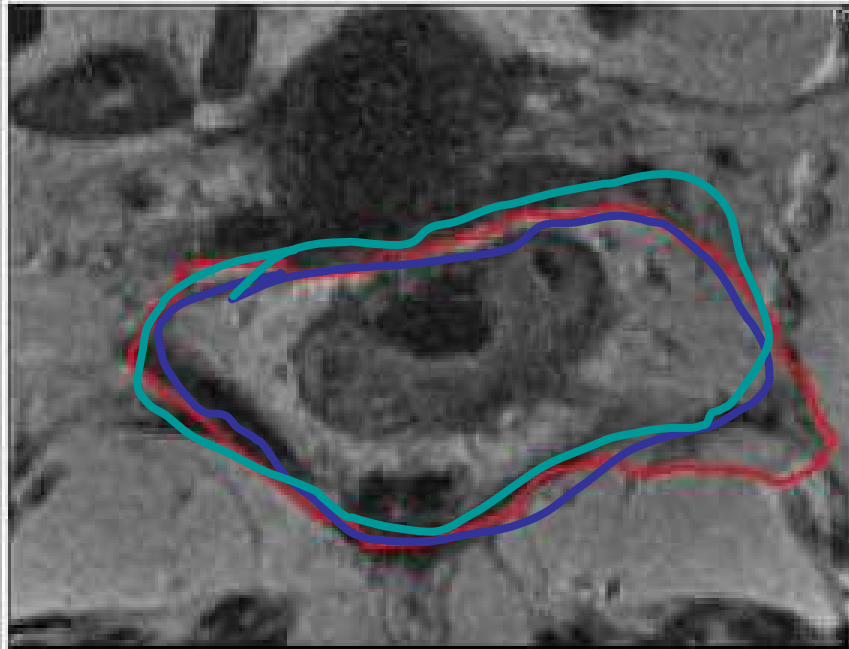


Clinical Cases

Delineation test

Question 1: Rectal cancer delineation attempts

Now click on: Acceptable delineation



Feedback

Your delineation hits the spinal column. We invite you to:

[Read theory](#)

chapter IX on 3d visualization.

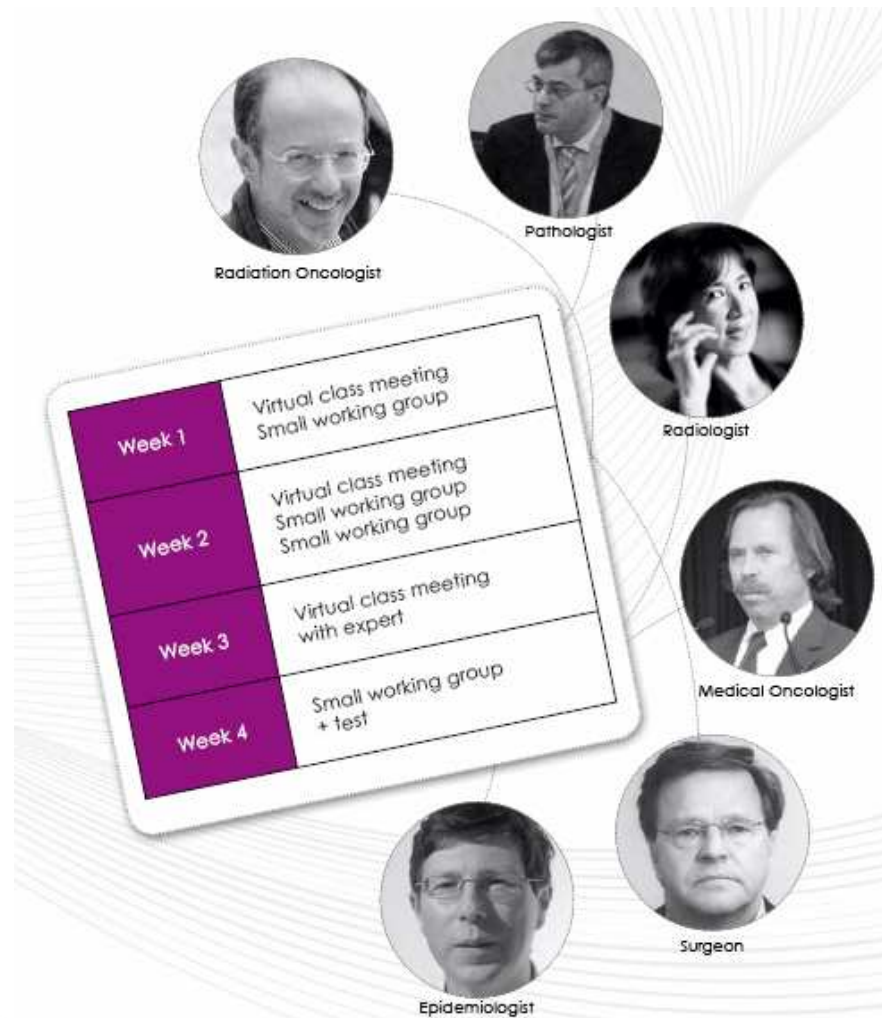[Try again](#)

taking theory information into account.

Multi-user contouring tool



Virtual Classroom Agenda



EAGLE

ESTRO Applications for Global Learning



Further Information and to Apply
education@estro.org



ESTRO 27 /// 14-18 September 2008 /// Göteborg, Sweden